



PATIENT

Ben Widell

PRESENTING CLINICAL SIGNS

History: New heart murmur noted at wellness exam. Sedated with Gabapentin.

SPECIES

Feline

ELECTROCARDIOGRAPHIC FINDINGS

A six lead ECG is available at 25mm/s; 10mm/mV. The average heart rate is 176bpm with a largely regular rhythm. The rhythm is sinus in origin, with a p for every QRS complex and vice versa. The P wave morphology is positive with a normal dimension. Normal PR. The QRS morphology is positive with normal dimension. MEA is normal. No ectopic beats, pauses or dysrhythmias observed.

BREED

DSH

ECG diagnosis: Normal sinus tachycardia.

SEX

Male Neutered

ECHOCARDIOGRAM FINDINGS

2D, m-mode, color flow and doppler imaging is available. The left ventricular wall is normal in dimension. There is a mildly hyperechoic endocardium consistent with mild fibrosis. The papillary muscles are normal in size and hyperechoic. The endocardium appears normal. The left atrium is normal in size. The right atrium is normal in size. The right ventricle appears normal. The mitral valve is normal in structure and mobility. Normal flow through both the RVOT and LVOT. Trace TR. Normal velocity. No AI or PI. No pleural or pericardial effusion seen. No obvious cardiac tumors.

AGE

4 years

CARDIAC CHART

WEIGHT

12.76lbs

INTERPRETED BY

Maggie Machen
Lamy, DVM, DACVIM
(Cardiology)

FELINE CARDIAC PARAMETERS	BODY WEIGHT (kg)	HR (BPM)	IVSd (cm) (Moise, Pipers)	LVIDd (cm) (Moise, Pipers)	LWVd (cm) (Moise, Pipers)	FS (%)	EF (%)
NORMAL PARAMETER	-----	150-240	0.35-0.55	<2 (mean 1.5)	3.5-0.55	35-67	80-100
PATIENT	4.6	210	0.47	1.35	0.41	64	94
FELINE CARDIAC PARAMETERS	LA/AO (Boon)	LA/AO HEART BASE (Swe) (Abbott)	LA 2D short axis Base view (cm) (Abbott)		LVOT VEL (m/s)	RVOT VEL (m/s)	E max (m/s)
NORMAL	<1.5	<1.3	<1.2		<1.6	<1.3	<0.9
PATIENT	1.3	1.2	1.1		1.1	1.3	NM
<p><i>*Note: All measurements based upon multi-modal images and methods. An average value is reported.</i> Adapted from June Boon, Veterinary Echocardiography, 1998 Abbott J & MacLean H JVIM 2006;20: 111-119, Moise et al. Am J Vet Res 47:1476, 1986. Pipers et al. Am J Vet Res 40:882, 1979.</p>							

IMAGING PERFORMED BY

Jenna Walsh, CVT

HOSPITAL NAME

West Hills Animal Hospital

REFERRING VET

Dr. Remcho

INVOICE

26135

DATE

8/31/22

INTERPRETATION OF THE FINDINGS & FURTHER RECOMMENDATIONS

Overtly normal cardiac structure and function. The LV wall thickness is normal and there is no evidence of elevated left atrial pressure. No obvious congenital issues are documented. No cause for the murmur is identified in this study, making it likely physiologic in origin. No additional issues are identified. The ECG is unremarkable with a normal sinus tachycardia.

Given these findings, no medications are indicated. It is important to note that phenotypic HCM can develop at any phase of life in cats and often does not accompany a heart murmur or PE abnormalities. Periodic screening is ideally recommended in all cats.



PATIENT

Ben Widell

No cardiac contraindication for general anesthesia at this time.

Recommend recheck echocardiogram in 1 year to screen for any progressive changes.

SPECIES

Feline

BREED

DSH

SEX

Male Neutered

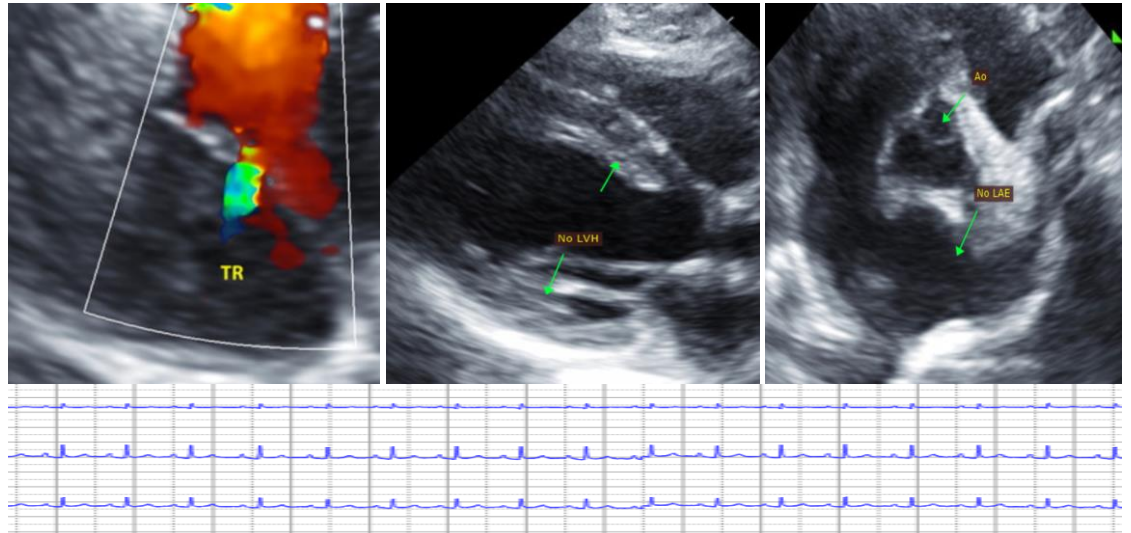
AGE

4 years

WEIGHT

12.76lbs

IMAGES



INTERPRETED BY

Maggie Machen Lamy, DVM, DACVIM (Cardiology)

The information and recommendations provided are based on the images presented by the referring veterinarian. No evaluation can be communicated regarding pathology that was not visible in the image/video clips provided.

Thank you for this referral. This report was generated using transcription software, and minor dictation errors may be present. If the clinical or image interpretation does not parallel your findings or if I can be of any further assistance, please contact me.

IMAGING PERFORMED BY

Jenna Walsh, CVT

Maggie Machen Lamy, DVM
 Diplomate of the American College of Veterinary Internal Medicine (Cardiology)
 info@sonopath.com

HOSPITAL NAME

West Hills Animal Hospital

REFERRING VET

Dr. Remcho

INVOICE

26135

DATE

8/31/22